

Greseli in practica ENG

-
- Barbat, 54 ani
 - MP: picior "cazut" drept de 1 luna, fara durere lombara, insotit de parestezii pe fata laterala a gambei si picior drepte
 - RM lombosacrat normal
-

O prima greseala

- ❑ Inceperea ENG fara o anamneza si o examinare obiectiva minutioasa
-

-
- Istoric: de la 35 de ani prezinta episoade (zile-saptamani) de picior "cazut" drept insotit de parestezii membre superioare
-

Obiectiv neurologic

- Paretezii pe fata laterala a gambei si piciorului drept + degetele III-V mana stanga
 - Hipoestezie membre inferioare pana la 1/2 inferioara a coapselor
 - Scadere de forta musculara segmentara in teritoriul peronierului drept
-

CIDP?

A doua greseala

- In diagnosticul de CIDP se examineaza toate cele 4 membre
-

Internare pentru continuarea investigatiilor

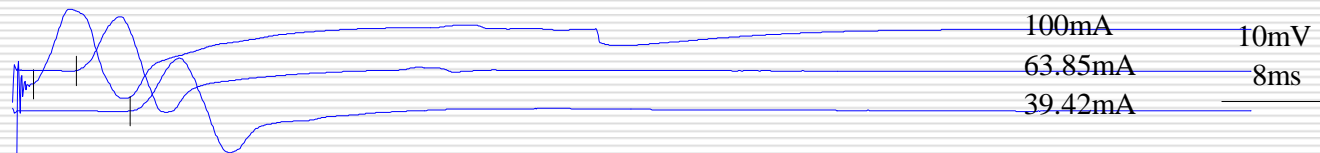
- Punctie lombara normala
 - Hipergamaglobulinemie cu aspect policlonal ceea ce sugereaza o infectie cronica
 - Restul imunologiei: normala, Ag HBs, Ac antiVHC negativi
-

VCM membre superioare

R Medianus	LD	Ampl	VC	F
Palm-APB	1,7	7,5		
Wrist-palm	5,2	5,5	26,9	-
Elbow-wrist	9,2	5,3	53,5	

Right Medianus


- palm - APB
- wrist - APB
- bel elb - APB



L Medianus	LD	Ampl	VC	F
Palm-APB	2,2	8,5		
Wrist-palm	5,3	6,6	29,0	31,3
Elbow-wrist	9,2	5,9	52,4	

Left Medianus

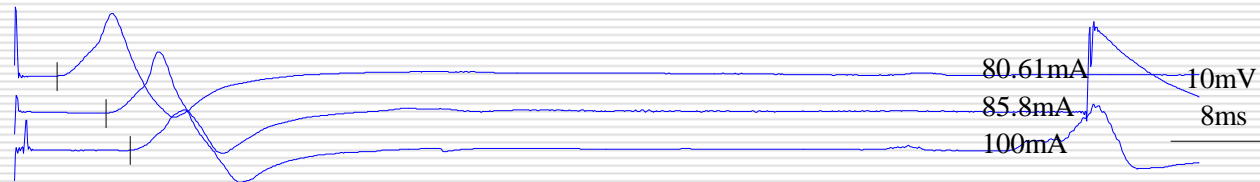
- palm - APB
- wrist - APB
- bel Elb - APB



R Ulnaris	LD	Ampl	VC	F
Wrist-ADM	3,6	6,6		
Be elb-wrist	7,8	6,3	51,2	31,2
Ab elb-be elb	9,8	4,2	40,0	

Right Ulnaris

- Wrist - ADM
- Be Elb - ADM
- Ab Elb - ADM

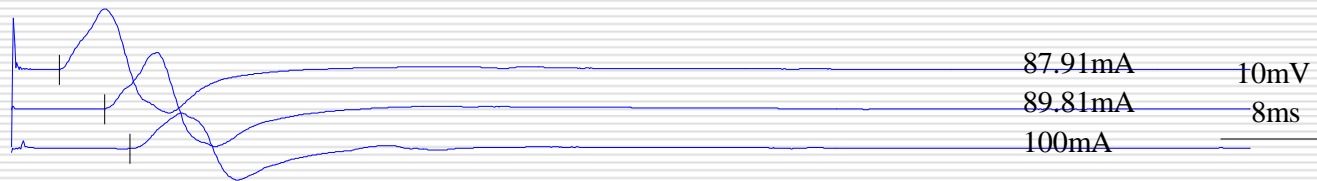


L Ulnaris	LD	Ampl	VC	F
Wrist-ADM	3,8	6,1		
Be elb-wrist	7,5	5,7	56,8	33,2
Ab elb-be elb	9,6	3,6	31,0	

Stim

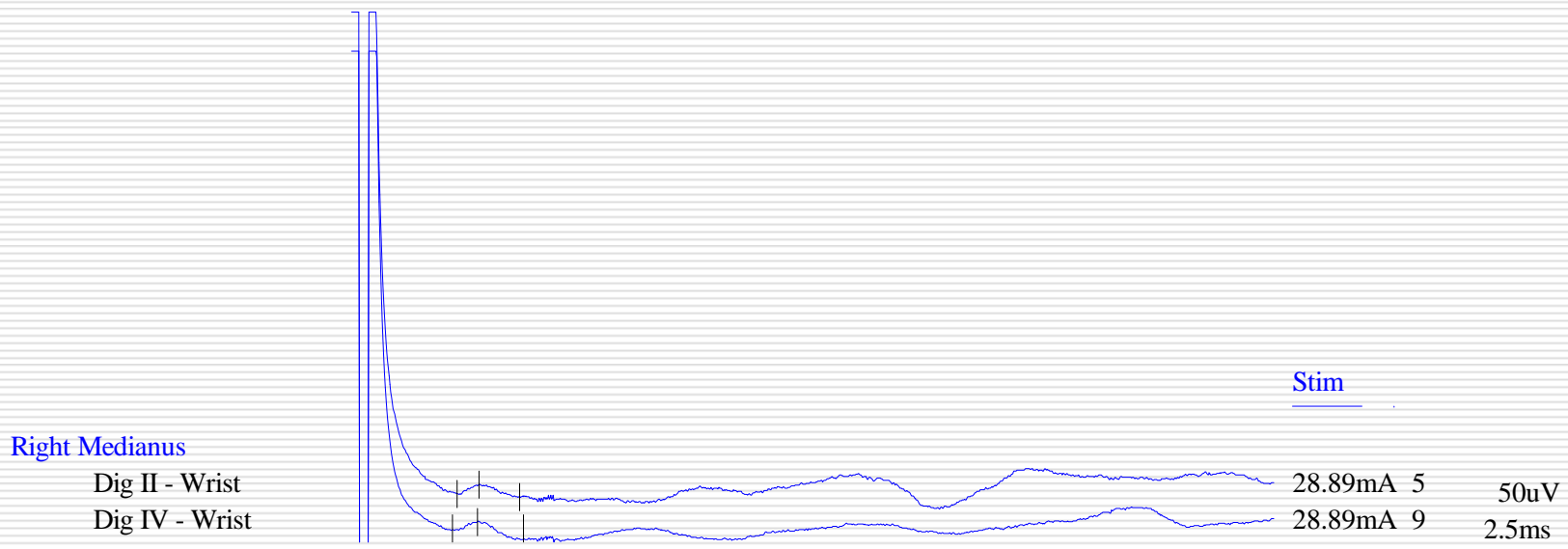
Left Ulnaris

Wrist - ADM
 Be Elb - ADM
 Ab Elb - ADM



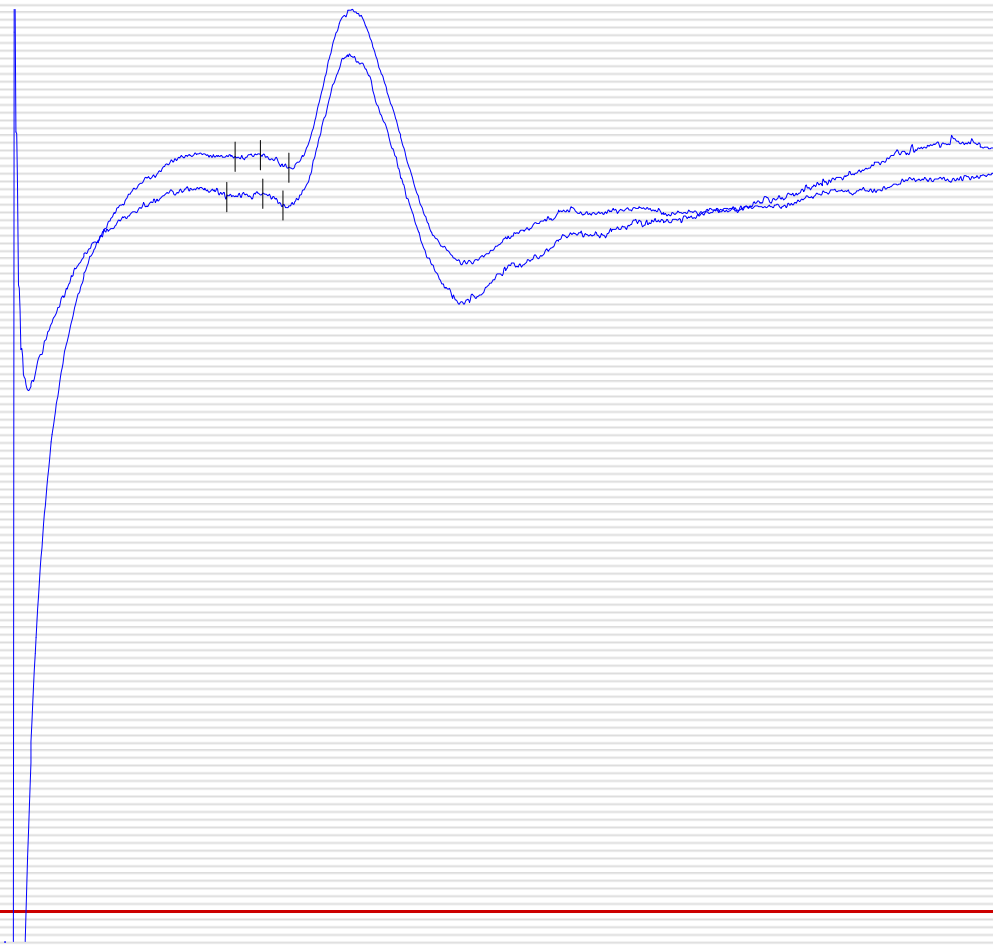VCS membre superioare

R/L Medianus	LD	Ampl	VC
	3,4/3,2	6,4/8,6	38,9/44,0
R/L Ulnaris	6,4/6,3	1,5/0,9	26,8/20,5



Right Ulnaris

Dig V - Wrist
Dors.Br - Wrist



Stim

21.69mA	9	20uV
21.69mA	5	2.5ms

CIDP?

O alta greseala

- ❑ Incercarea de incadrare, in ciuda nepotrivirilor, a datelor obtinute intr-un anumit tipar
-

Cea mai mare greseala

- Cautarea prezentei/absentei antecedentelor eredocolaterale
-

-
- ❑ In acest caz atat tatal cat si fratele au probleme cu mersul
 - ❑ Fratele si cei 2 fii ai sai-Chartcot-Marie-Tooth
 - ❑ Sora si fiica aparent fara probleme de mers
-

Concluzie

- ❑ Polineuropatie ereditara demielinizanta
 - ❑ HNPP-AD deletia genei PMP22, crs 17p11.2
 - ❑ CMT1A-AD duplicare si mutatia PMP22, crs 17p11.2
 - ❑ CMTX-AD mutatia genei conexinei32, crs Xq13-22
-